
SURGICAL TECHNIQUE

Repair of Orbital Fractures Using MEDPOR TITAN OFW and MEDPOR TITAN MAX OFW Implants

John Shore, MD
Texas Oculoplastic Consultants
Austin, TX

stryker[®]

Administer perioperative antibiotics per standard of care.

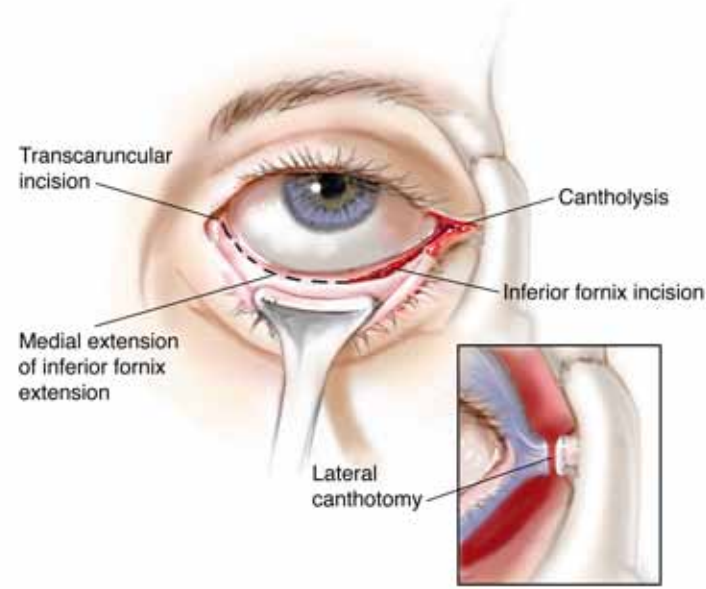


Figure 1: Perform a transconjunctival inferior fornix incision to the orbital floor with lateral canthotomy and cantholysis to expose the orbital fracture. The inferior fornix incision may be extended medially via a transcaruncular incision if needed to provide additional access to the medial wall.

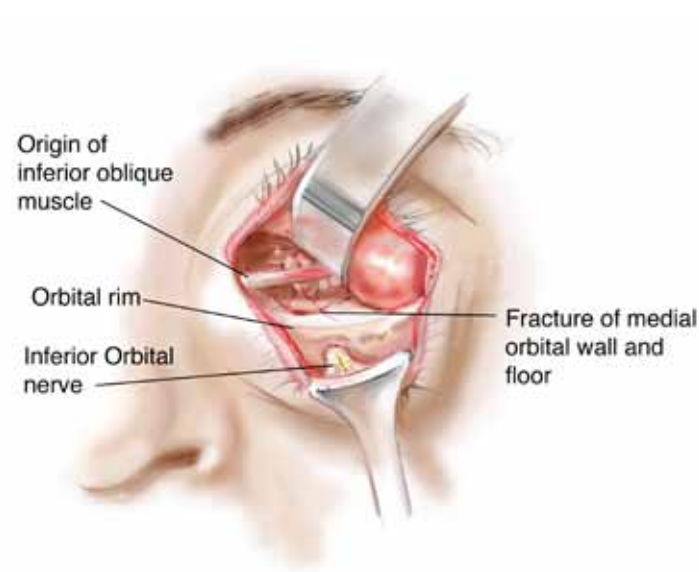


Figure 2: For large floor and medial wall fractures, and especially with the transcaruncular incision, the origin of the inferior oblique muscle may be in the way and impede placement of the implant in proper position or limit exposure for proper identification and visualization of the fracture site.

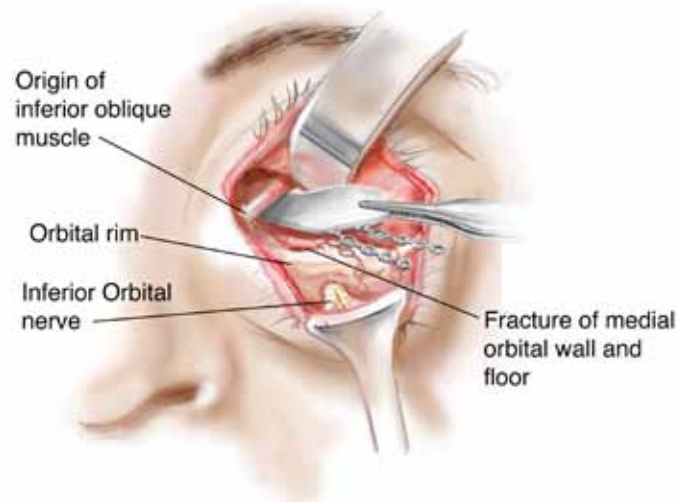


Figure 3: If the inferior oblique muscle can be retracted the implant may be slid behind it.

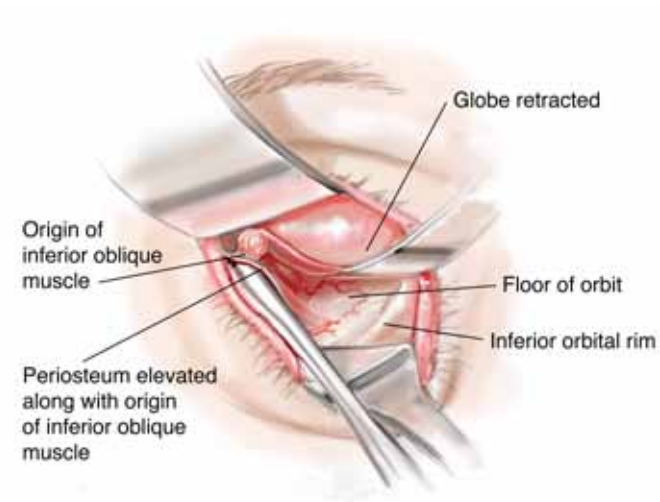


Figure 4: If the inferior oblique muscle restricts access to the fracture site, its origin may be lifted from the bone along with the periosteum, and allowed to return to its original position after the implant is placed.

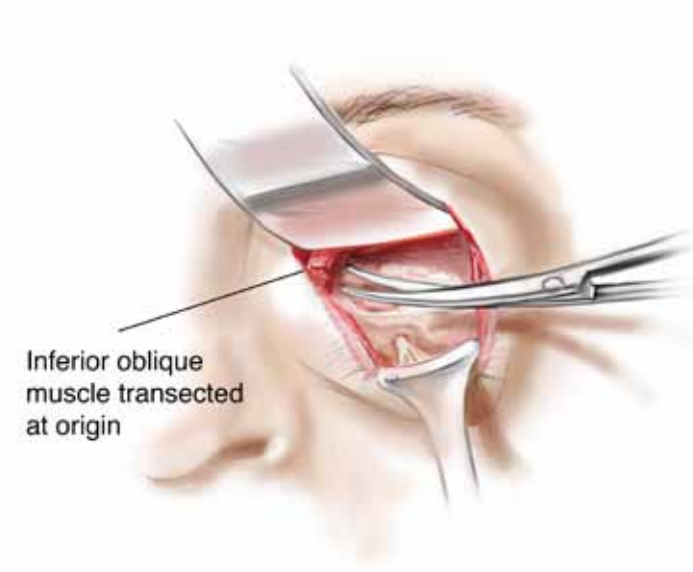


Figure 5: Alternately, the inferior oblique may be transected near its origin. The inferior oblique muscle should be cut as close to the origin as possible so as not to denervate the muscle to the inferior oblique. Dissection is the preferred method over transection as there is less bleeding.

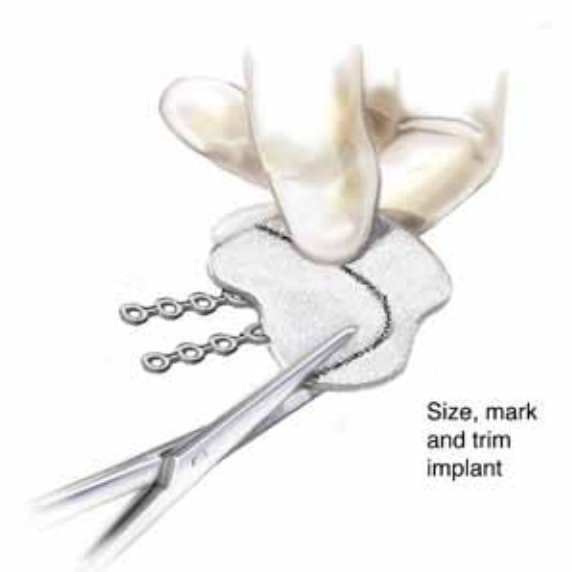

Figure 6: Size and trim the MEDPOR TITAN or MEDPOR TITAN MAX OFW Implant of any excess material. The final shape of the implant should overlap the bony defect, if possible.

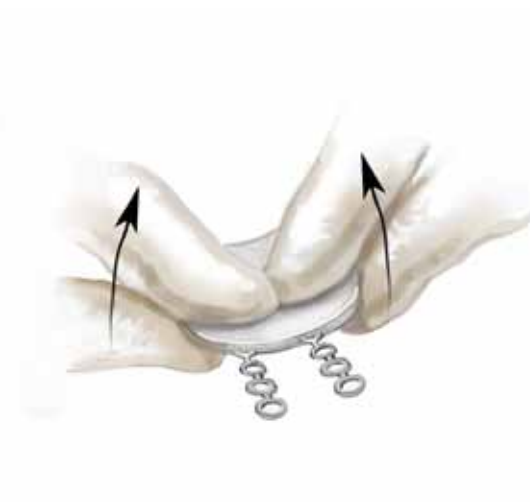


Figure 7: Bend the implant before placement to conform to the shape of the orbit.

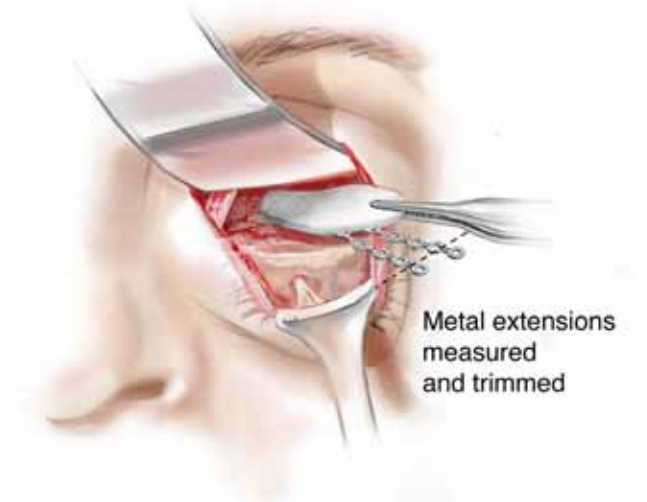


Figure 8: During placement of the implant, orbital soft tissue (fat, muscle, nerve, etc) must not be incarcerated between the implant and the bone. The orbital soft tissue will come to rest on top of the implant once the implant is properly positioned. Final placement and position of the implant should be checked prior to trimming titanium extensions.

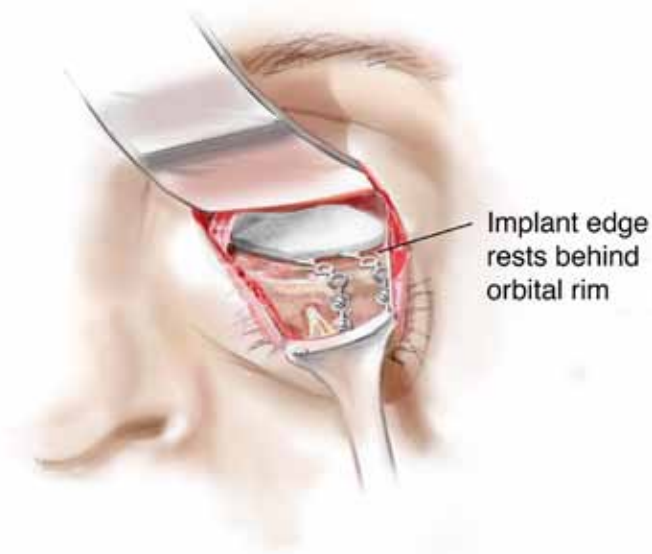


Figure 9: The implant may be secured with two titanium screws. The implant edge should rest behind the orbital rim. After final placement of the implant, forced duction tests should be preformed to ensure free movement of the globe.

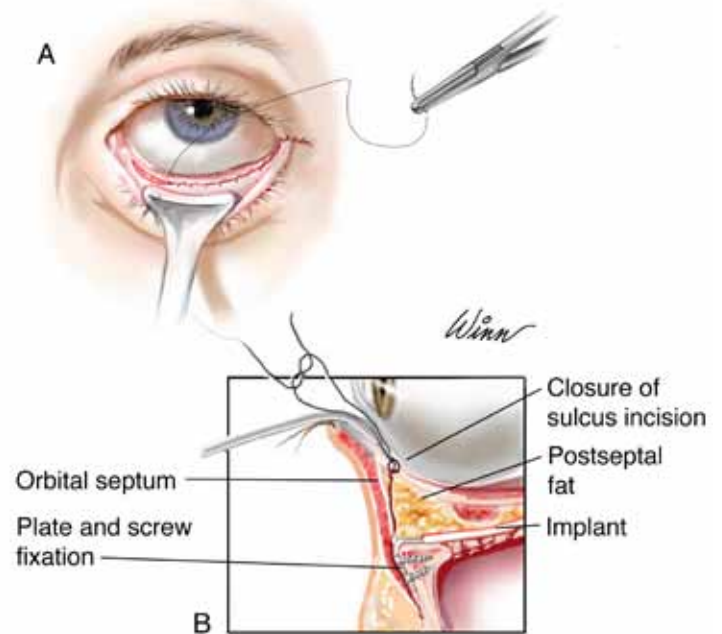


Figure 10: When the wound is closed care should be taken to respect the various tissue planes so as not to incarcerate orbital fat or fascia within the wound closure as this may lead to lower eyelid retraction or positional ectropion (the eyelid turning outward).

A surgeon must always rely on his or her own professional clinical judgment when deciding whether to use a particular product when treating a particular patient. Stryker does not dispense medical advice and recommends that surgeons be trained in the use of any particular product before using it in surgery.

The information presented is intended to demonstrate the breadth of Stryker product offerings. A surgeon must always refer to the package insert, product label and/or instructions for use before using any Stryker product. Products may not be available in all markets because product availability is subject to the regulatory and/or medical practices in individual markets. Please contact your Stryker representative if you have questions about the availability of Stryker products in your area.

Distributed with the permission of John W. Shore, MD